



PATIENT

Flint Hurt

SPECIES

Feline

BREED

DSH

SEX

M

AGE

6

WEIGHT

10.2

INTERPRETED BY

R. McKenzie Daniel,
DVM, DABVP
(Canine and Feline)

IMAGING PERFORMED BY

Jenn

HOSPITAL NAME

Rockaway Animal
Hospital

REFERRING VET

Dr Maniar

INVOICE 23385

DATE
12/30/2025

PRESENTING CLINICAL SIGNS

vomiting

Abnormal PE/Chem/CBC/UA Results: WBC 18.6

ULTRASONOGRAPHIC EXAMINATION OF THE ABDOMEN

Urinary System

The urinary bladder, trigone, cystourethral junction, and visible pelvic urethra to a depth of 2 cm exhibited normal thickness and tone. Anechoic urine was present in the lumen with no evidence of urine/lumen sediment, mineral, or calculi. The ureteral papillae were normal. The ureters were not visible which is normal. No evidence of inflammatory or neoplastic changes was noted.

Normal size and margination were present in the kidneys. A normal 1:3 cortex / medulla ratio and normal corticomedullary definition were maintained. The echogenicity of the cortex was similar to or slightly less than normal liver parenchyma while the medulla echogenicity was hypoechoic to the cortex with no evidence of pelvic dilation. The left kidney measured 4.0 cm in length. The right kidney measured 3.8 cm in length.

The area of the aortic trifurcation was free of pathology.

Adrenal Glands

The left and right adrenal glands were not definitively visualized. No obvious pathology was present in the area of the bilateral adrenal glands.

Spleen

The spleen exhibited a finely textured and homogenous parenchyma which was hyperechoic to the liver and renal cortical parenchyma. The capsule was smooth and regular without apparent expansion. The splenic vasculature at the hilus was normal in volume with no evidence of congestion or thrombosis. Acute to chronic inflammatory, neoplastic, or benign parenchyma changes were not noted.

Liver/Gallbladder

The liver was subjectively normal in size, structure, and contour. The liver parenchyma was uniform and hypoechoic to the spleen with a mild coarse echotexture. Normal vascular volume. The hepatic and portal vasculature were normal in appearance without signs of congestion. The gallbladder was non-distended in size with thin walls and primarily anechoic luminal content. The cystic and common bile ducts were normal.

Gastrointestinal

The stomach presented intact wall layering with a normal wall layer ratio. The lumen of the stomach was empty with no signs of ileus, obstruction or foreign material.

The small intestine presented intact wall layering with 1:3 muscularis/mucosa ratio. The lumen of the small intestine was empty with no signs of mechanical/metabolic ileus, obstruction or foreign material. The duodenum wall measured 0.27 cm width. The jejunum wall measured 0.20 cm width.

Normal visible colon wall layers were present with apparent formed feces in lumen.



PATIENT

Pancreas

Flint Hurt

The area of the pancreas was sonographically normal.

SPECIES

Free Abdomen

Feline

No evidence of peritoneal effusion was present.

BREED

Intermittent mildly prominent to enlarged mesenteric lymph nodes were present. The lymph nodes were essentially isoechoic to adjacent omentum without evidence of peripheral inflammation and maintaining a normal width: length ratio (<0.5). An example measured 0.7 cm in width.

DSH

ULTRASONOGRAPHIC FINDINGS

SEX

Primary

M

- Normal empty gastrointestinal tract
- Normal area of the pancreas
- Intermittent mild mesenteric lymphadenopathy- suspect mild reactive hyperplasia or potential lymphadenitis owing to non-structural inflammatory bowel episode

AGE

6

INTERPRETATION OF THE FINDINGS & FURTHER RECOMMENDATIONS

WEIGHT

No evidence of gastrointestinal foreign material or obstructive pattern. Gastrointestinal support should prove beneficial. Recheck sonogram indicated if non-responsive or progressive gastrointestinal signs.

10.2

INTERPRETED BY

R. McKenzie Daniel,
DVM, DABVP
(Canine and Feline)

IMAGING PERFORMED BY

Jenn

HOSPITAL NAME

Rockaway Animal
Hospital

REFERRING VET

Dr Maniar

INVOICE

23385

DATE

12/30/2025



PATIENT

Flint Hurt

SPECIES

Feline

BREED

DSH

SEX

M

AGE

6

WEIGHT

10.2

INTERPRETED BY

R. McKenzie Daniel,
DVM, DABVP
(Canine and Feline)

IMAGING PERFORMED BY

Jenn

HOSPITAL NAME

Rockaway Animal
Hospital

REFERRING VET

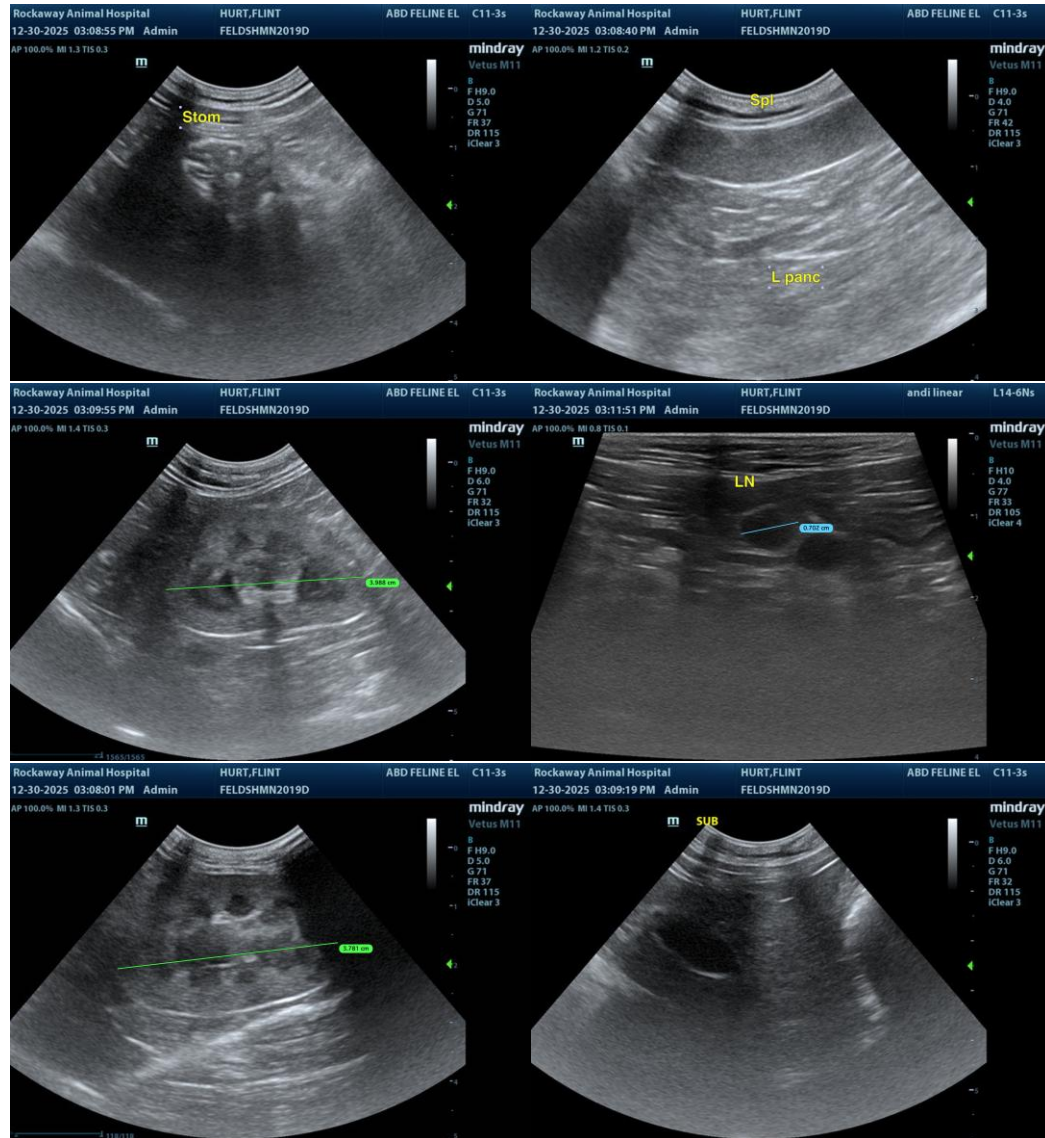
Dr Maniar

INVOICE

23385

DATE

12/30/2025





PATIENT

Flint Hurt

SPECIES

Feline

BREED

DSH

SEX

M

AGE

6

WEIGHT

10.2

INTERPRETED BY

R. McKenzie Daniel,
DVM, DABVP
(Canine and Feline)

IMAGING PERFORMED BY

Jenn

HOSPITAL NAME

Rockaway Animal
Hospital

REFERRING VET

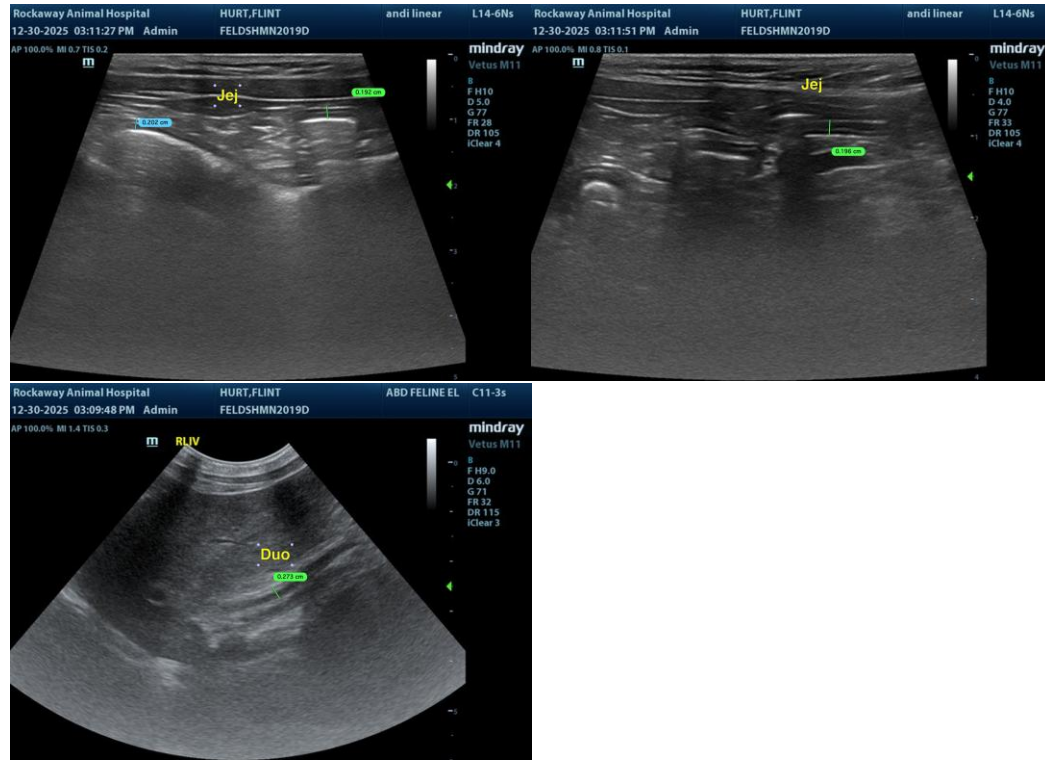
Dr Maniar

INVOICE

23385

DATE

12/30/2025



The information and recommendations provided are based on the images presented by the referring veterinarian/sonographer. No evaluation can be communicated regarding pathology that was not visible in the image/video clips provided.

Thank you for this referral. If the clinical or image interpretation does not parallel your findings or if I can be of any further assistance, please contact me.

R. McKenzie Daniel, DVM, DABVP (Canine/Feline Practice)
info@sonopath.com